

# Situation CRITICAL

A Publication for Providers of Trauma and Critical Care

Fall 2011



## This issue:

- An Unparalleled Tradition of Emergency Care
- Knee Dislocations
- Clinical Feature: Emergency Tongue Trauma
- Partner Profile: The Minnesota State Patrol



North Memorial

# Table of Contents

- 1 Letter from Dr. Lilja
- 2 North Memorial Ambulance
- 4 North Memorial in the News
  - 2011 Advanced Trauma Life Support (ATLS)
  - Emergency Medicine and Trauma Update: Beyond the Golden Hour
  - Tornado Stirs Outpouring of Help
  - Long, Hot Summer Trauma and Emergency Care Conference
  - North Memorial Receives Trauma Re-Verification
  - Holly Berg Receives North Memorial Faculty Teaching Award
- 7 Clinical Feature: Knee Dislocations
- 8 Clinical Feature: Emergency Tongue Trauma
- 18 New Providers in Emergency Medicine
- 20 Partner Profile: The Minnesota State Patrol

Cover photograph “Tasting the Sun” by Ethan Cooper.

## Learn More Online

You can download previous issues of *Situation Critical* at [northmemorial.com](http://northmemorial.com) and also find us on Facebook, Twitter and YouTube. Links can be found at [northmemorial.com](http://northmemorial.com) (click on the social media icons from the bottom of any page).



---

*Situation Critical* is published two times a year to inform trauma and critical care providers about news and events at North Memorial and to provide helpful information related to patient care. If you would like to be added to (or removed from) our mailing list, please contact Sue Lundquist, *Situation Critical* editor, at (763) 520-1475. You can also send an e-mail message to [Sue.Lundquist@NorthMemorial.com](mailto:Sue.Lundquist@NorthMemorial.com). Your questions, comments and suggestions for upcoming articles are also welcome.

# Letter from Dr. Lilja

Dear Readers:

When it comes to providing top-notch emergency and trauma services, North Memorial has a long, storied history. We celebrate some of that history in this edition of *Situation Critical* with a look back at the first 50 years of North Memorial Ambulance Service. I believe it's an interesting look not just into North Memorial's past, but the evolution of our industry as well.

I'm proud to announce that North Memorial has continued its leadership position in emergency and trauma care by earning a re-verification of its status as a top-level trauma center in March. As you may know, North Memorial Medical Center first became a Level I Trauma Center in 1998. North Memorial also earned a Level II verification for its pediatric trauma care program.

In keeping with the spirit of tradition, this issue also profiles the Minnesota State Patrol, a partner of North Memorial for nearly 35 years. Our joint efforts in emergency training have helped to save many lives.

Unfortunately, this past summer was notable for the tornado that ripped through North Minneapolis, coming within a mile of our hospital. North Memorial treated 43 people who were injured by the tornado. However, more than just providing medical care for our neighbors, we provided support in other ways – through contributions of cash, food and other donations.

Here's hoping that fall proves to be much safer, as well as reinvigorating.

Sincerely,



G. Patrick Lilja, MD, FACEP  
*Medical Director, North Memorial Ambulance*



# North Memorial Ambulance

## AN UNPARALLELED TRADITION OF EMERGENCY CARE North Memorial Ambulance Service Celebrates 50 Years

In 1961, President Kennedy established the Peace Corps. In Germany, construction of the long-standing Berlin Wall had just begun. American consumers were getting their first look at electric toothbrushes and disposable diapers, while paying 27 cents a gallon for gas and a mere four cents for a first-class postage stamp. And in Robbinsdale, Minnesota, a booming suburb of Minneapolis, a hospital still in its infancy launched an ambulance service.

At first, North Memorial had two ambulances that transported an average of five patients a day. Today, North Memorial Ambulance Service has grown into the region's largest medical transportation service and boasts one of the biggest fleets of any private ambulance service in the country.

The decision to start North Memorial Ambulance fifty years ago was fueled by the passion and imagination of Vance DeMong, North Memorial's first administrator, whose interest in providing the best emergency care capabilities was legendary.

"Vance had a great interest in emergency care and his goal was to put North Memorial on the map," recalls Scott Anderson, North Memorial CEO from 1981 to 2005. "He felt that North Memorial could take over this part of the country by addressing the need for improved emergency medical services. Vance was very forward thinking in terms of his goals and visions."

North Memorial Ambulance started with a staff of six people who were trained in first aid. Drivers, known as "ambulance attendants" in those days, provided a service that was little more than a glorified ride to the hospital. The first ambulances, souped up Cadillacs that evoke images of the hearse transporting President Kennedy after his assassination, bear virtually no similarity to the ambulances of today, which are essentially emergency rooms on wheels.

The early years of North Memorial Ambulance, under the leadership of Chet Peterson, were characterized by attention to detail, quality and training, hallmarks that continue to this day. Chet, known for constantly checking ambulances to ensure they were clean, spotless and in tip-top shape, established North Memorial's emphasis on education from the outset. One of his first priorities as director was to ensure that all staff were certified in the medical competencies of the day. He also became the

first manager of North Memorial's Emergency Medical Services Education, which has since grown into one of the largest providers of emergency care training in the Upper Midwest.

The hungry, young ambulance service, considered the most visible part of an emergency services operation that was deep and comprehensive, grew steadily and was quick to embrace the latest medical technologies. By 1971, call volume had increased to 17 runs a day and training certifications had increased to advanced first aid and CPR. In 1973, North Memorial Ambulance was an early adopter of telemetry to measure heart activity, and ambulances were upgraded to Advanced Life Support (ALS), meaning that an advanced level of care could be provided to patients by a two-person team including a paramedic and an EMT trained in coronary care.

The 1980s saw perhaps the most rapid and sweeping changes to the ambulance service and medical transportation, in general. In 1981, North Memorial staffed six ALS units with 46 medics and eight EMTs, and had stations in Robbinsdale, Brooklyn Park, Long Lake and Rogers. By the end of the decade, through expansion and acquisition, the fleet grew to include 30 ALS and BLS (Basic Life Support) units, and operations extended to Brainerd, Crosslake, Aitkin, Princeton and Faribault.

One of the bigger developments of the decade occurred in 1985, when North Memorial took its medical transportation skyward with North AirCare, an airborne emergency service that consisted of a critical care helicopter and fixed-wing air ambulance. Operations were initially located at Fleming Airfield in St. Paul (and now take place at the Crystal airport). Thanks to North Memorial's emergency care outreach program, trauma center status and statewide reputation, the endeavor was a great success even though competition in the air care market was stiff.

Today, North Memorial boasts a full-service operation that includes 125 ambulances, eight helicopters, 750 employees and a nationally recognized dispatch center. It responds to 70,000 calls a year and delivers essentially every level of care. There are 30 bases in nine designated regions that cover an area the size of Massachusetts.

Another key development in the growth of North Memorial Ambulance has been the contribution of Pat

# North Memorial Ambulance

Lilja, MD, who became the first medical director in 1977 and continues in that capacity today. “Dr. Lilja’s “load and go” philosophy – meaning minimizing the time spent at the scene on the highway or in the home, and getting the patient to the tertiary care center as soon as possible – was emphasized, and it’s a philosophy that guides the organization to this day,” says Jerry Moen, North Memorial Ambulance director from 1984 to 1992. Dr. Lilja also established invaluable connections with emergency services personnel throughout much of the region.

The growth of the ambulance service, along with its sterling reputation for providing state-of-the-art emergency medical services, has played a key role in the growth of North Memorial. “Without the ambulance service, I don’t think that North Memorial would have achieved its trauma center status,” says Gary Pearson, director of Outstate Ambulance and Support Services.

“We’ve continually grown in size from our small beginnings ... and really never stopped growing,” says Gary. “Yet we’ve retained the feeling that we’re a family more than a business.” In addition to the overall North Memorial ambulance family, there’s a separate family that exists within each distinct location and region. “Each region has its own independent culture, yet it’s still part of the overall North Memorial culture,” says Gary.

The importance of maintaining a local identity is particularly helpful in the many small communities in which the ambulance service operates. In so many ways – whether providing coverage for community events, providing demonstrations to school children, or helping to set up emergency response teams for local businesses – each local ambulance service has become a part of the fabric of the community and a trusted partner.

While access to cutting edge emergency care, deployment of the latest vehicle tracking technology and a series of acquisitions have contributed to the success of NMAS, it’s North Memorial’s loyal and dedicated staff that are most responsible for an incredible 50 years of success. The loyalty of its employees – some of whom have remained since the late 1960s – are beyond question.

Pat Coyne, current director of North Memorial Ambulance, is cut from the family mold, having first started working at North Memorial as a paramedic in 1973. “The longevity of our managers and staff reflect how much we enjoy what we do and how much pride we take in our jobs,” says Pat. “We’re always seeking to do things a little better and to go above and beyond what’s necessary.”

It’s been a tradition for a half century.

## North Memorial Ambulance Services Milestones

- 1961 – North Memorial Ambulance starts with a staff six that averaged five patients a day
- 1968 – North Memorial Ambulance begins providing EMS education to hospital and emergency care staff
- 1971 – Call volume increases to about 17 runs a day
- 1977 – Staff size grows to 30 (24 medics, four EMTs and two admin)
- 1978 – North Memorial Ambulance opens dedicated dispatch center that handles an estimated 10,000 911 calls in first year
- 1981 – Staffing increases to 46 medics and 8 EMTs and covers 6 ALS units
- 1982 – North Memorial Ambulance begins providing tactical medics to the Minneapolis regional FBI SWAT team. North Memorial’s dignitary coverage, which was in place for President Nixon, continues today.
- 1985 – North Memorial Air Care, a branch of North Memorial’s medical transportation arm, begins service
- 1987 – North Memorial acquires ambulance services in Brainerd, Crosslake and Aitkin, making the Brainerd region the largest area served by North Memorial in the state.
- 1990 – The Wisconsin region expands with the addition of Spooner-Shell Lake operations. Coverage now includes 12 townships and two cities.
- 1992 – Mike Parrish becomes director of North Memorial Ambulance Services
- 1995 – Under a contract with Fairview Health Care System, North Memorial Ambulance begins operations in Forest Lake
- 1998 – North Memorial Ambulance establishes a bike medic team to provide paramedics to outdoor community events
- 2000 – North Memorial Ambulance responds to more than 60,000 911 calls per year
- 2004 – The Communications Center (dispatch) becomes an accredited center of excellence, one of only ten in the world to earn such a distinction
- 2007 – A fifth helicopter base is established in Bemidji
- 2011 – North Memorial Ambulance, with 750 employees, 12 vehicles and eight helicopters, is well positioned for future growth

# North Memorial in the News

## 2011 Advanced Trauma Life Support (ATLS) *December 1-2, 2011*

This program was developed by the American College of Surgeons Committee on Trauma and designed to assist physicians in providing the first hour of emergency care to trauma patients. Training combines didactic lectures and practical skill stations, allowing time to perfect skills in the initial assessment, management and stabilization of phases of trauma patients. At the conclusion of the program, participants should be able to:

1. Assess the patient's condition rapidly and accurately
2. Resuscitate and stabilize the patient according to priority
3. Determine if the patient's needs exceed a facility's capabilities
4. Arrange appropriately for the patient's definitive care
5. Ensure that optimum care is provided

The ATLS course includes a surgical skills practicum. Topics include:

- Initial Assessment & Management
- Airway & Ventilatory Management
- Shock

- Thoracic & Abdominal Trauma
- Head & Spine Trauma
- Musculoskeletal Trauma

**Registration:** You may register online at <http://www.northmemorial.com/professionaledu/cme.cfm> or by calling North Memorial EMS Education at (763) 520-5451.

**Course Location:** North Memorial Education Center, 3500 France Ave. North, Robbinsdale, MN. Parking is free.

**Sponsored by:** Section of Trauma/Surgical Critical Care

**Presented by:** Minnesota Committee on Trauma & North Memorial Medical Center, Emergency Medical Services Education

---

## Emergency Medicine and Trauma Update: Beyond the Golden Hour *November 17, 2011*

### Course Information

Sponsored by the Surgery and Emergency Medicine Departments of Regions Hospital, Hennepin County Medical Center, North Memorial Medical Center, Mayo Clinic, St. Mary's Medical Center – Duluth, University of Minnesota Medical Center – Fairview, along with Regions Hospital Nursing Departments, Gillette Children's Specialty Healthcare and the Center for Continuing Professional Development, HealthPartners Institute for Medical Education.

DoubleTree by Hilton Hotel Bloomington – Minneapolis South (formerly Sheraton Bloomington Hotel, Minneapolis South), Bloomington, Minnesota

### Featuring:

- Plenary Sessions
- Parallel Curricular Tracks for Physicians and Nurses
- Hands-on Breakout Sessions

### Preliminary program includes hot topics in:

- Minnesota Pediatric Trauma
- Early Recognition of Critical Illness and Injury
- Applying Lessons from the Military to Civilian Health Care
- National Conference Bullet Points
- Influential Papers That Will Change Your Practice and Breakout Sessions
- Eye Emergencies
- Pediatric Sedation
- Large-bore and Small-bore Chest Tube Insertion
- Radiation Emergencies
- Ultrasound

### For More Information

For more information about the conference, please visit [http://www.healthpartners.com/ime/continuing-education/DEV\\_017434](http://www.healthpartners.com/ime/continuing-education/DEV_017434).

# North Memorial in the News

## Tornado Stirs Outpouring of Help

The tornado that occurred on Sunday, May 22 struck in North Memorial's back yard. Like other neighbors in North Minneapolis, North Memorial, with a rich tradition of helping the community, lent a helping hand.

In addition to treating the physical wounds of 43 people who came to North Memorial, the organization and its staff helped in other ways. In the week following the tornado, North Memorial employees, with support from the North Memorial Foundation and the Executive Medical Staff Committee, donated food, bottled water, clothing and cash totaling \$34,000.

"We live in a wonderful community where people really come together during difficult times," says Larry Taylor, North Memorial Chief Executive Officer. "We were pleased to come forward with charitable hearts to mend the emotional and material needs of our community."

Just how close did the tornado come to hitting the hospital? This video (<http://www.youtube.com/watch?v=-mTEkknqTCQ>), taken from atop the hospital's helipad,

depicts the twister moving northeastward just to the southeast of the hospital. However, the tornado damaged North Memorial Clinic – Camden Physicians Minneapolis located on Webber Parkway. The clinic subsequently re-opened on May 30.




## Long, Hot Summer Trauma & Emergency Care Conference: March 9-10, 2012

The The 23rd Annual Long, Hot Summer trauma and emergency care conference will take place Friday, March 9 and Saturday, March 10, 2012 at the Northland Inn in Brooklyn Park, MN.

Mark your calendar and save the date for one of the Midwest's very best conferences on trauma and emergency care. We've added more hands on workshops and lined up an impressive panel of national and local speakers to address the latest information for emergency service providers of all kinds.

We're back at the Northland Inn with more expansive exhibit space and the infamous all you can-eat refreshment kiosks and meals, but with cheaper room rates of only \$109/night. Not to be missed is the traditional Friday night dance with a popular country western band.

You can get more information about the Long Hot Summer of 2012 after December 1 in the following ways (individual brochures will not be mailed):



- Follow us on Facebook (<http://www.facebook.com/pages/North-Memorial/49342595955>) or Twitter ([twitter.com/northmemorial](http://twitter.com/northmemorial))
- Email [ems.education@northmemorial.com](mailto:ems.education@northmemorial.com) and asked to be put on the email distribution list
- Download and print the brochure at <http://www.northmemorial.com/emsd>

Don't miss this great conference that offers timely education and a fun way to catch up with colleagues and co workers.

Request program information by calling (763) 520-1570 and leaving your name and address.

## North Memorial Receives Trauma Re-Verification

**N**orth Memorial Medical Center, a Level I Trauma Center since 1998, earned re-verification of its status as a top-level trauma center in March. The Level I verification, determined by the American College of Surgeons (ACS) after an exhaustive review of the trauma program, is the highest verification a trauma care center can achieve.

North Memorial also earned a Level II verification for its pediatric trauma care program. In recent years, the ACS started issuing separate verifications for adult and pediatric trauma care programs.

“The re-verification validates that we’re continuing to provide trauma care for both adults and children that is of the highest quality,” says Kevin Croston, MD, FACS, chief medical officer and surgical director of Trauma Services. “This accomplishment represents the combined efforts of a large number of North Memorial staff and is something we should all be proud of.”

Trauma care at North Memorial has long been a great source of pride, dating back to the vision of the organization’s “founding fathers” and demonstrated by the early adoption and improvement of emergency care.

For hospitals, the ACS verification program helps to evaluate and improve trauma care by providing an

objective, external review of a trauma center’s resources and performance. It is conducted by a team of trauma experts who come to the hospital and assess a variety of program features, including commitment, readiness, resources, policies, patient care and performance improvement.

As part of the requirements for being a Level I Trauma Center, a trauma program must possess resources to provide the entire spectrum of care to address the needs of all injured patients – from the pre-hospital phase through the rehabilitation process. Some of these resources include having a complete team of trauma-trained surgeons and subspecialists available 24 hours a day to treat adult and pediatric patients, advanced radiology facilities and injury prevention specialists. A Level I trauma center is also required to participate in research, public education and outreach – services North Memorial provided long before receiving its initial verification from the ACS.

Trauma centers grew into existence out of the realization that traumatic injury is a disease process unto itself requiring specialized and experienced multidisciplinary treatment and specialized resources. According to the Center for Disease Control and Prevention (CDC), injuries are the leading cause of death for children and adults ages 1–44.

---

## Holly Berg Receives North Memorial Faculty Teaching Award

**H**olly Schrupp Berg, MD, received the North Memorial Faculty Teaching Award in June. Each year, the first and second year Hennepin County Medical Center emergency medicine residents elect one North Memorial emergency medicine physician to receive this award. The award was presented to Dr. Berg for her outstanding commitment to resident education. Last year’s winner was Dr. Adina Connelly, who also joined North Emergency Physicians in 2009.



## KNEE DISLOCATIONS

*By Andrew F. Arthur, MD, Twin Cities Orthopedics*

Multi-ligament injuries of the knee resulting in a dislocation event are rare but serious injuries which may be limb-threatening if not treated properly. Associated nerve and vascular injuries often complicate the treatment and necessitate the cooperation of a multi-disciplined approach including an orthopedic surgeon, trauma surgeon, vascular surgeon, and emergency medicine team.

Knee dislocations result in disruption of at least three of the four major ligaments about the knee. High-energy sports trauma or motor vehicle crashes constitute the majority of knee dislocations, usually as the result of severe torsional or hyperextension injuries. Due to the high-energy nature of these injuries, the incidence of associated fractures is as high as 60%. Furthermore, the incidence of ipsilateral peroneal nerve injury is about 30%, and associated vascular popliteal injury can be as high as 30-50%.

Injury to the popliteal artery typically follows two patterns. Hyperextension injuries cause a stretching to the vessel which ultimately will lead to complete rupture. The second pattern involves a torsional force to the vessel which causes deep contusion and intimal damage. This intimal vascular injury may result initially in only partial vascular compromise. However, if this situation is not recognized or is left untreated, eventual occlusive thrombus will form and a limb-threatening situation will result. For this reason, under no circumstances should an abnormal vascular exam be left untreated or attributed to simple vascular spasm.

Once the diagnosis of a knee dislocation is made, early reduction of the dislocation should be obtained followed by close observation of the neurovascular structures. Closed reduction in the emergency room setting is preferable, followed by placement of a knee immobilizer with the knee in full extension. Pulses should be palpated and doppler ankle-brachial indices (ABI) should be obtained. Discrepancy of the ABI of less than 0.9 as compared to the unaffected extremity warrants further vascular exam such as CT angiography.

Once the knee has been appropriately reduced and the vascular status has been deemed stable, the patient can be prepared for surgical stabilization of the knee once all other associated injuries are optimized. At this point, the patient may be transferred to a facility or surgeon that specializes in the stabilization of these complex ligament injuries.

Surgical treatment of multi-ligament knee injuries typically follows in two stages. The first stage involves stabilization of either of the collateral ligaments that have been disrupted (i.e. MCL or posterolateral corner). Within the first 1-2 weeks of the initial injury, a successful open anatomic repair of these structures can often be achieved. Second-stage arthroscopic ACL and PCL reconstructions can then be performed 4-6 weeks later once the knee has gained some level of motion. This two-staged approach optimizes the ability to successfully repair collateral structures while also diminishing the incidence of stiffness that may accompany a single-staged approach.

With the assistance and cooperation of a multi-disciplined team, these difficult limb-threatening injuries can be optimized, with the ultimate goal of returning the patient to his or her pre-injury level of function.

For more information about knee replacements or to refer a patient, please contact North Memorial's Joint Replacement Center at (763) 520-1800. If you have a patient with a knee dislocation requiring emergent care, please call the Physician Consult line at (800) 230-2413.

### References:

Fanelli GC, Feldmann DD, Edson CJ, Maish D: The Multiple Ligament-Injured Knee. Orthopaedic Sports Medicine, DeLee and Drez ed. 2nd edition, pp. 2111-2121, 2003.

## EMERGENCY TONGUE TRAUMA

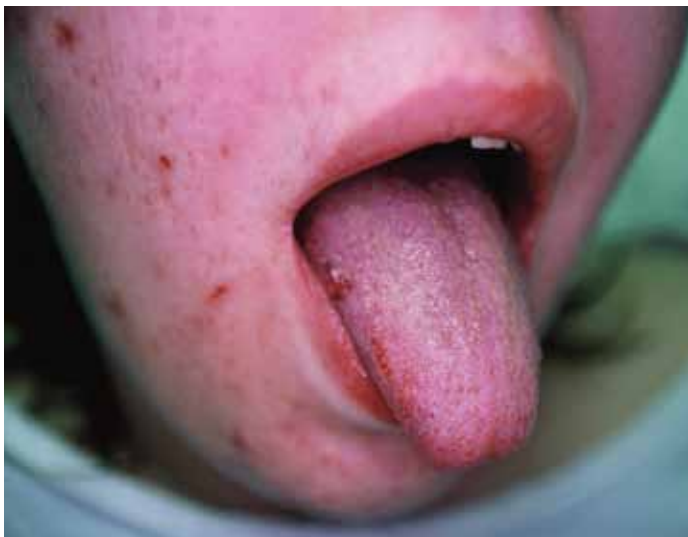By David J. Roberts, MD, and Barbara G. Roberts, JD

### Introduction

**T**rauma to the tongue is fairly common. The tongue is comprised primarily of muscles, covered by a mucous membrane. It contains glands, sensory organs, and four pairs of extrinsic muscles. Small bumps called “papillae” cover the upper surface of the tongue, surrounded by taste buds. The tongue is necessary for the proper articulation of the jaw, food manipulation, swallowing, and unimpeded speech. It also protects the airway, provides taste, and it may have a sexual or cosmetic function depending on the patient. Any impact to the tongue, chin, or face can result in trauma to the tongue.

### Accidental Tongue Injuries

Lacerations of the tongue are often the result of a fall, seizure, bite to the tongue, or impact. A bite to the tongue can help distinguish a seizure from other spells. A *lateral* bite to the tongue was 100% specific for a tonic-clonic seizure according to Benbadis et al. Only 1 in 45 patients with syncope suffered a tongue laceration, and that laceration was at the tip of the tongue. Pseudoseizures rarely result in glossal injury. One autopsy study found that a tongue bite helped to distinguish death from a seizure from cardiac death.

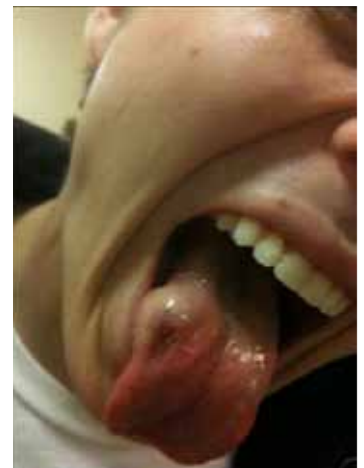
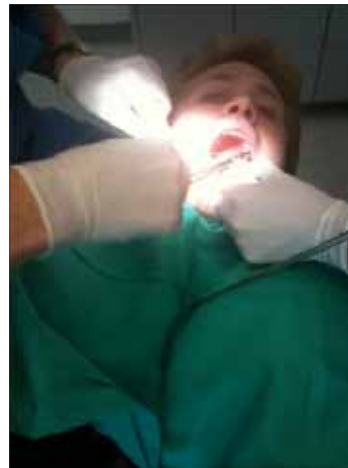
Careful inspection of the right side of the tongue helped confirm a seizure in this patient.

Most tongue injuries are accidental and minor. It's rare to meet someone who doesn't recall having at least one minor tongue injury in childhood. Because people can generally relate to accidental tongue injuries, stories of celebrity tongue trauma sometimes receive wide press coverage.

Such was the case for MTV's *The Hills* star, Spencer Pratt, in March 2010. Pratt, 26, was reportedly walking his Pomeranian dog while holding a toy rope in his mouth. During an ensuing game of tug-of-war with his dog the rope slipped out, causing Spencer to bite down through his own tongue and requiring several stitches. Spencer was unable to speak for several days, but his injuries healed.

### Intentional Tongue Injuries



MTV's *The Hills* star, Spencer Pratt, received stitches for 2010 accidental tongue injury. Photos printed with permission of *SCelebs.com*, *Celebrity Gossip*.



Famous tongues are a part of American pop culture. KISS band member Gene Simmons has enjoyed commercial success over the past 30 years due in large part to his identifiable makeup and tongue. A rock-and-roll icon, Simmons reportedly has his tongue insured for \$1,000,000.

# Clinical Feature

Although the majority of tongue injuries in the U.S. are accidental, emergency department personnel should be sensitive to the fact that tongue injuries may be secondary to a crime or physical abuse. Such was the case of an alleged rapist whose tongue was bitten off by a woman in California. The woman bit down, severing the man's tongue (a piece about the size of a half-dollar coin) while trying to defend herself from a vicious attack by a registered sex offender. The alleged rapist was arrested at the emergency room of the hospital where the victim was being treated after claiming he had cut his tongue on a can. Police recovered the severed tongue at the woman's apartment, but physicians could not reattach it.

A similar incident occurred in Connecticut during June 2011 when a woman bit off a large piece (one-inch long) of a man's tongue during an alleged, attempted rape. Police found the tongue and an enormous amount of blood at the scene, and notified area hospitals to be on the lookout for an alleged rapist who was missing part of his tongue. Police arrested the alleged attacker when he sought treatment for his tongue at a walk-in, massage and chiropractic clinic.

Domestic abuse can also play a role in tongue injuries. In 2010 an elderly man from Wisconsin underwent surgery to have his tongue reattached after his wife allegedly bit off his tongue during a kiss. The victim had difficulty speaking when he called 9-1-1 and he had to rely on visual signs and handwriting to communicate with EMS responders. The victim's wife was charged with a felony (mayhem and physical abuse) and she was ordered to undergo a mental health evaluation pending a criminal hearing. Surgery to reattach his severed tongue was successful. The victim's wife was diagnosed with a mental condition for which ongoing treatment was ordered in lieu of incarceration.

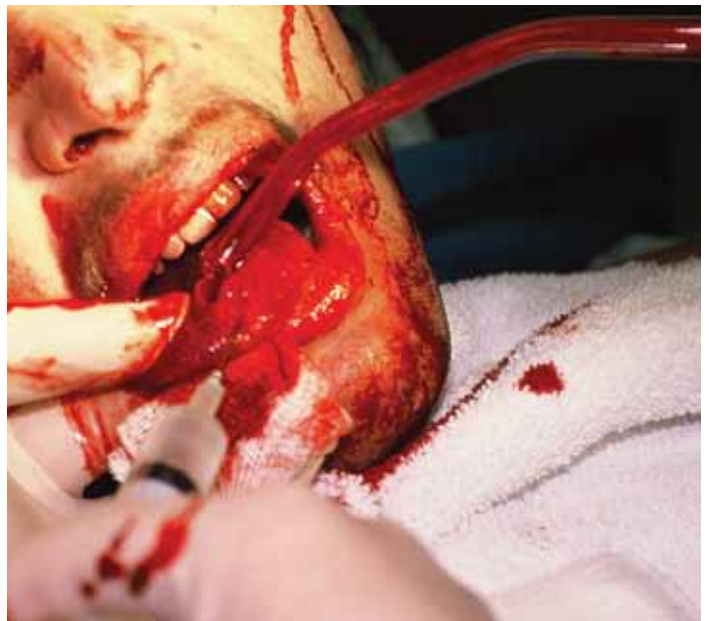## Human or Animal Bites to the Tongue

Patients who are bitten on the tongue by a person or an animal should see a physician if the skin is broken. The general rule is that bites that break the skin should be handled as contaminated wounds. In addition to concerns about rabies and tetanus, a bite victim may get an infection by bacteria or viruses deposited in the tongue tissue – particularly if the patient's immune system is compromised. The bacterial inoculum of bite wounds is high in oral microflora because of the organisms contained in saliva. There may also be a concern regarding the potential transmission of viruses (e.g., human immunodeficiency virus (HIV), hepatitis B virus (HBV),

and hepatitis C virus (HCV)). Patients should be advised to bring any tissue that has been bitten off to the emergency department; in some cases, it can be reattached.

## Treatment of Tongue Lacerations

Tongue lacerations typically bleed heavily because of the rich supply of blood in that area.



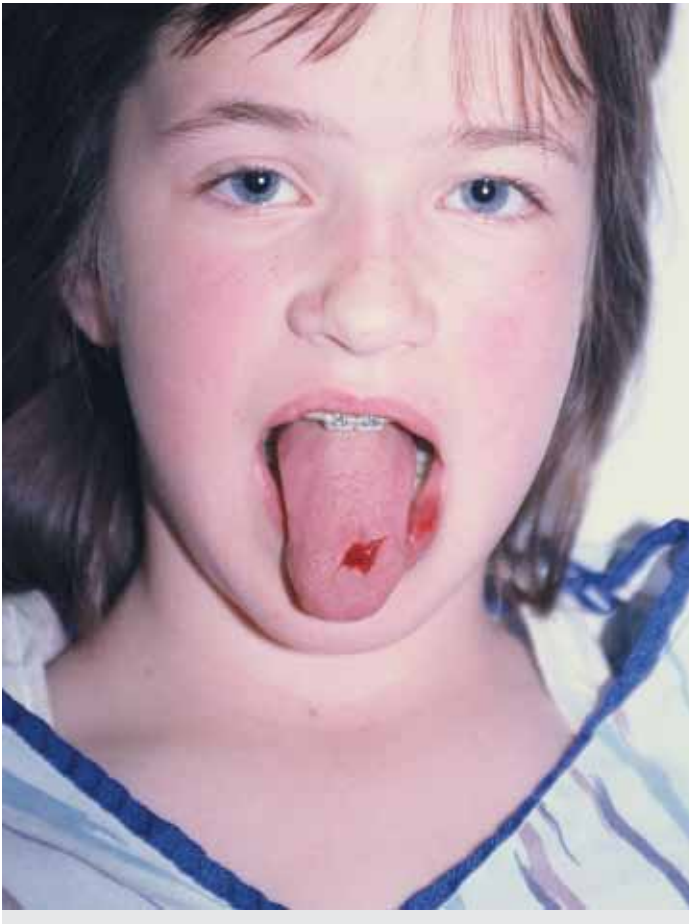*This large tongue laceration bled profusely. Hemostasis and wound closure was achieved with interrupted 4-0 Vicryl sutures.*

It is helpful to reassure and educate patients that the bleeding associated with tongue injuries is seldom cause for alarm, as well as to reassure parents of small children that the bleeding is not dangerous. Preschoolers, in particular, will react to their parents' level of fear and anxiety, and if their parents remain calm it will facilitate good medical care. Fortunately, it can be explained that the rich supply of blood to the tongue will actually aid healing.

Minor lacerations of the tongue typically occur when soft tissue comes into contact with teeth or braces. Usually, minor lacerations of the tongue heal satisfactorily without medical assistance. Most pediatric tongue lacerations do not require repair.

Larger lacerations of the tongue may need to be sutured, especially if the cut is long or deep. Stitches may also be indicated when bleeding will not stop, or when a cut

# Clinical Feature



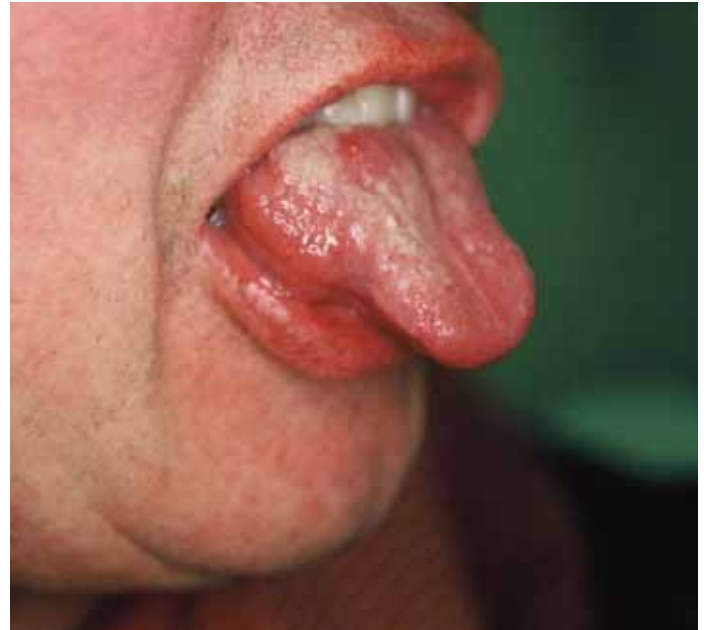*This girl bit her tongue when her head struck the front seat after her vehicle was rear-ended. It healed well without stitches.*

gapes or changes shape as the tongue moves. Avulsion or amputation injuries also may necessitate stitches, but a large avulsion or tongue amputation is very serious and requires a specialist, usually otolaryngologist or oral surgery specialist. In some cases, a surgeon can replant an amputated tongue with satisfactory results.

<b>Table 1: Indications for repair of a tongue laceration</b>
1. The laceration is greater than 2 cm.
2. Flap laceration.
3. Laceration that continues to bleed.
4. Laceration that involves the edge of the tongue.
5. Laceration that passes completely through the tongue.
6. Laceration that bisects the tongue.

Many tongue lacerations that present in emergency departments can be properly treated there without a specialist. The goals of tongue laceration repair are to:

(1) close the wound; (2) minimize the risk of complications; (3) preserve mobility and the ability to position the tongue; (4) preserve speech articulation; (5) preserve the ability to swallow (deglutition); (6) preserve taste; and, in some cases, to (7) address cosmetic concerns (e.g., bisected or cleft tongue) or sexual concerns (e.g., STDs). Usually, sutured lacerations heal faster and have a lower risk of infection. Fortunately, tongues usually do not become infected.



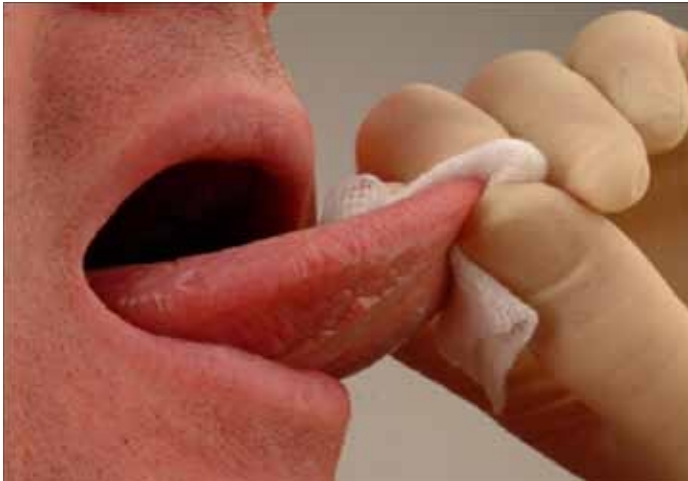*This diabetic patient's tongue developed an abscess, which could be incised and drained in the emergency department.*

When examining a tongue laceration, physicians should determine the cause of injury, assess the impact to the area, and pay close attention to the patient's lips, gums, inside cheeks, teeth, and jaw. Keep in mind that the tongue's color may be affected by substances the patient has ingested; similarly, tongue color may be affected by the presence of a tongue tattoo. Piercings and tongue jewelry should be removed and stored.

Whenever possible, the patient should stick out the tongue voluntarily as far as it can go so lacerations can be observed completely and the tongue can be examined for swelling, discoloration, contamination, and texture. If the tongue deviates to one side or the other, it may indicate that something is impacting the nerves affecting tongue movement. Physicians also should use a sterile piece of gauze to hold the tongue tip and then move it – gently but firmly – from one side to the other until the sides of the tongue can be fully examined. Pulling the tongue

## Clinical Feature

firmly forward, manipulate its position until the top and underside of the tongue can be fully examined, as well as the base of the tongue where it begins to turn down the throat. When observed directly from the front, the tongue and openings to the back of the mouth should appear symmetrical and not be swollen. Gaping of lacerations and the source of any bleeding during manipulations should be carefully observed.



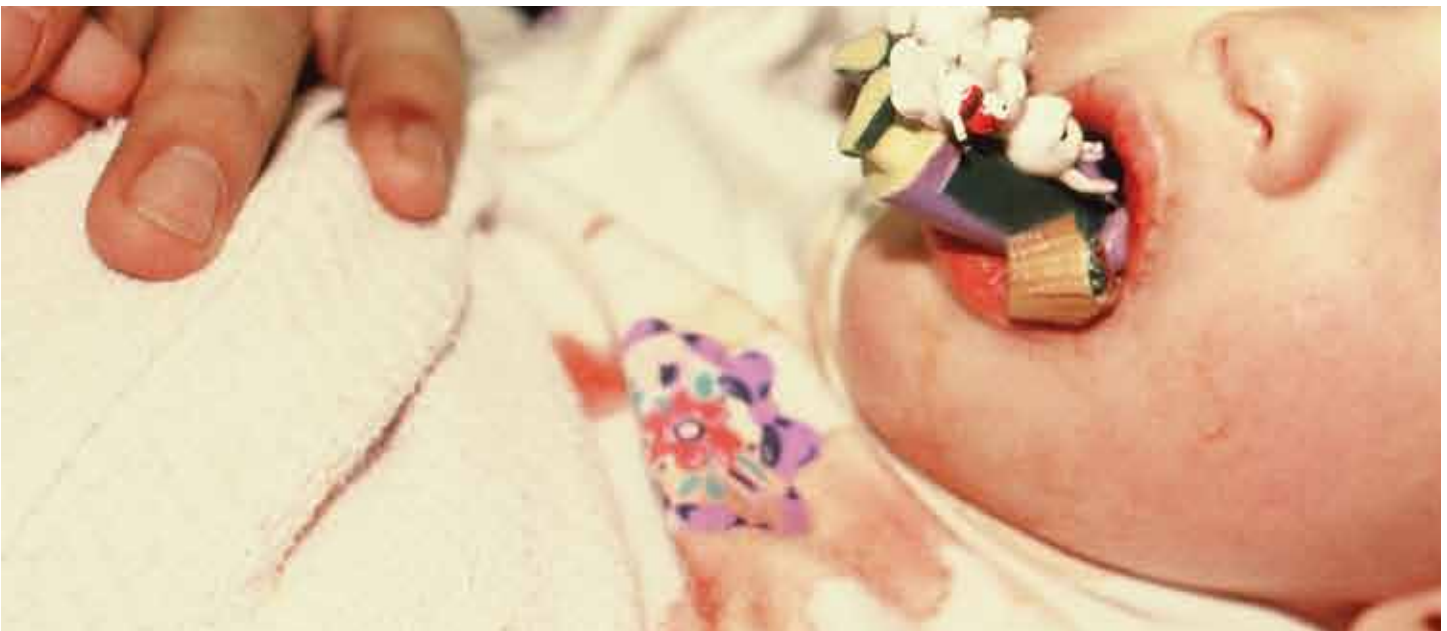*Photo courtesy of The Oral Cancer Foundation ©2011. While treating lacerations and tongue injuries, physicians may detect the presence of oral cancer or a pre-cancerous condition (e.g., lesions, white or red patch, difficulty moving the tongue, lumps, or any enlarged or thickened areas). Early detection and treatment of this disease is the key to survival. If suspicion of oral cancer arises during a tongue-related emergency, a biopsy is recommended.*

If the integrity of any tooth is compromised (e.g., chipped, cracked, tender, loose, or missing), tongue injuries must be managed in such a manner that tooth fragments are removed from the area and dental concerns are separately addressed. Similarly, physicians should pay close attention to whether a patient has any lip or tongue piercings and, if so, ascertain that there is no missing lip or tongue jewelry. In cases of suspected jaw fractures, tooth damage, missing teeth, bone fragments, lip or tongue jewelry, x-rays will be essential. Removing foreign bodies caught or impaled on the tongue can be challenging.

Medical treatment of tongue lacerations depends on the nature, size, and location of the cut. Bleeding can often be controlled with a cold compress or gauze applied with steady pressure to the wound. Ice or other cold compresses can reduce swelling, bleeding, and discomfort. A patient's tetanus status should be up-to-date. It is important that tongue injuries be thoroughly cleaned with antiseptic, saline, or a hydrogen peroxide rinse. Dirt and foreign matter should be removed from the wound.

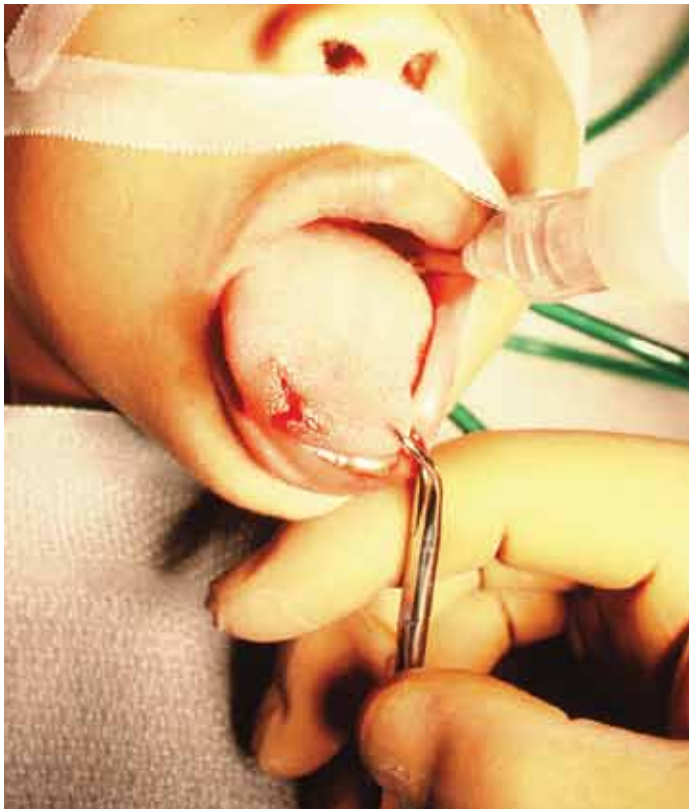The supine position (i.e., patient lies on back with face or front facing forward) is preferable for most tongue repairs. A common challenge for emergency medical personnel attempting to treat tongue lacerations is stabilizing and controlling the area of the tongue being sutured. It is helpful to grasp the tip of the tongue with gauze or a towel clip; if necessary, the tip of the tongue can be punctured and withdrawn with a large suture. Bite blocks may also be used in the awake patient to protect both the patient

*A hooked Christmas tree ornament became trapped on this child's tongue. It had to be removed in the OR.*



## Clinical Feature

and physician. The repair of a child's laceration in the emergency room will generally require moderate to deep sedation with an agent such as ketamine.



*This child's laceration to the edge of the tongue was repaired in the OR. Grasping the tongue with a towel clip aided the repair.*

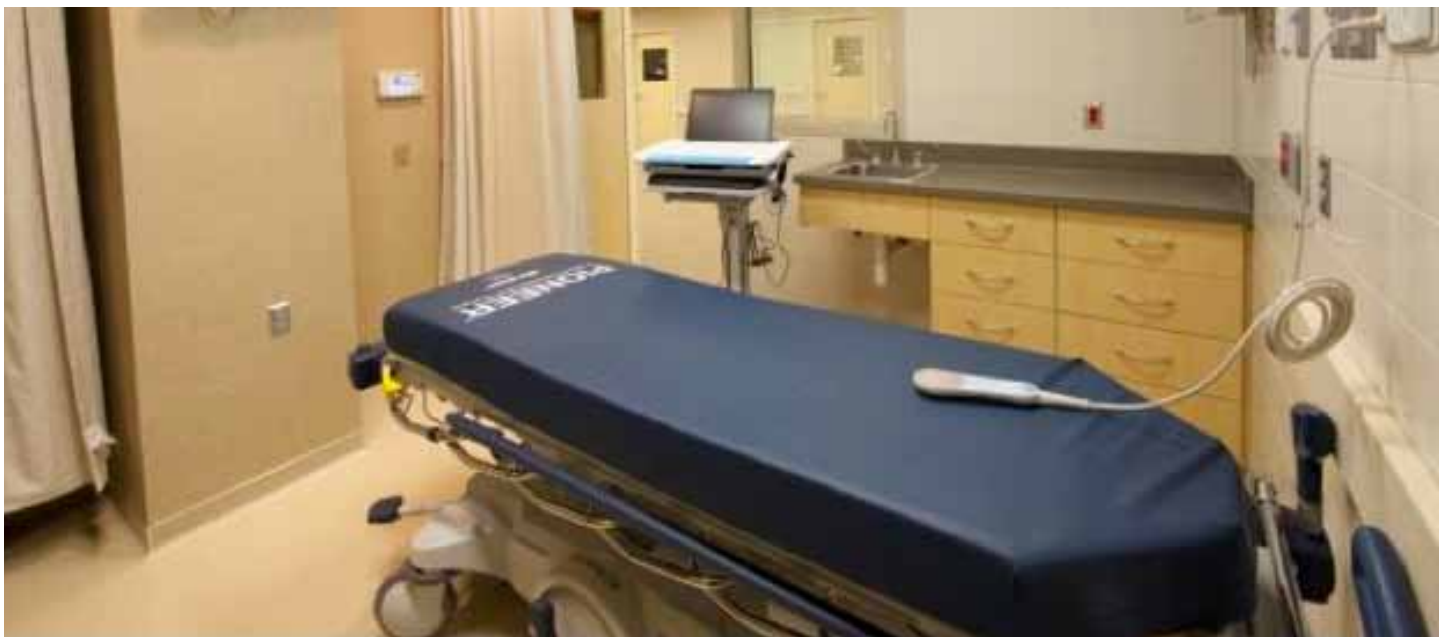During the treatment of tongue lacerations, emergency department personnel may elect to manage patient pain in several ways. Pain management options include: (1) topical anesthesia with 4% lidocaine on gauze for approximately five minutes; (2) local infiltration with 1% lidocaine with epinephrine; (3) lingual nerve block (anterior alveolar nerve block) for the anterior two-thirds of the tongue; (4) procedural sedation (i.e., sedatives or dissociative agents such as ketamine, with or without analgesics); or, (5) general anesthesia.

Repair is best performed with absorbable suture such as 4-0 chromic or Vicryl sutures. Nylon sutures should be avoided because the stiff end of the suture is uncomfortable in the mouth. To achieve good hemostasis and closure, the suture should pass deeply through all layers of the tongue. Burying the knot is also helpful.

Most tongue injuries require self-care following release from the emergency department. Provided the muscular layer of a lacerated tongue is closed, bleeding should be adequately controlled, motor function should return, and the mucosal layers should heal quickly. In appropriate cases, the use of antibiotics will be indicated following release from the emergency department. Use of prophylactic antibiotics for tongue injuries remains controversial, but are generally accepted for contaminated wounds.

Typically, self-care includes repeated gargling with dilute peroxide mouth rinses or salt-water solutions while the

*Tongue injuries are often treated in emergency rooms similar to this one at Maple Grove Hospital.*



wound heals. Upon release from the emergency room, patients with tongue lacerations also should be advised to watch for subsequent signs of infection, such as increased pain or tenderness, fever, purulent discharge or taste, excessive swelling, or cervical lymphadenopathy. Patients should be urged to seek medical assistance promptly in cases of suspected infection, tongue interference with speech, or difficulty swallowing. Bad breath is normal during the healing period. If it worsens, however, follow-up care is required.

During self-care for tongue injuries, it is advisable to encourage soft or bland diets for the first few days and to avoid solid, spicy, acidic foods, tobacco, and alcohol, because they can irritate or sting the tongue while it is healing.

## Prevention of Tongue Lacerations

Since many tongue injuries occur during impact sports, many tongue injuries can be prevented through the use of a safety mouth guard. Most mouth guards are made of soft plastic that is designed to fit the shape of the upper teeth and – in the case of some contact sports – both the upper and lower teeth. Generic mouth guards typically are available for purchase in sporting goods stores and custom-fit guards are typically available from dentists. For the majority of non-sports related injuries, proper seat belt and car seat usage will similarly reduce the risk of tongue-related trauma.

## Trauma Affecting Tongue Movement and Taste

Trauma that affects tongue movement usually is caused by nerve damage and it can result in difficulties with breathing, speech, chewing, and swallowing. Swelling, bruising, and lacerations resulting from such bites are common. Healing time is determined primarily by the severity of the tongue injury.

The sudden onset of a swollen tongue is frequently associated with glossitis. Common causes of glossitis include bacterial or viral infections (e.g., herpes simplex), irritation or injury from burns, teeth, or braces, or allergic reactions to toothpaste, mouthwash, plastic in dentures or retainers, and certain blood pressure medications. Tardive dyskinesia can also cause the tongue to batter against the teeth.

Trauma that affects taste may be caused by damage to the taste buds or nerve damage (the tongue typically identifies sweet, sour, bitter, and salty tastes, whereas other “tastes”

are a function of smell); however, taste irregularities are also commonly associated with infection and certain medications.

The importance of taste buds to patients should not be underestimated. Such was the case in 2009 when Lloyd’s of London insured the taste buds of Gennaro Pelliccia, Costa Coffee’s Italian Master of Coffee, for about \$13.78 million. According to Lloyd’s, “Pelliccia personally tastes every single batch of raw coffee beans at the company’s coffee roastery in London, before they are roasted and shipped to its stores.” Lloyd’s added that the “average tongue has approximately 10,000 taste “buds”... (and) this is not the first time Lloyd’s has insured a tongue. Wine tasters for supermarkets and wine merchants have also taken out policies.

## Tongue Burns

When a tongue is burned, it can be extremely painful. If a heat burn occurs, it is helpful to apply something cool to the tongue immediately to help dissipate the heat and reduce damage to tongue cells. Crushed ice, cold yogurt, Popsicles®, frozen fruit, or ice cream are practical methods to cool the tongue at home and may negate an unnecessary visit to the emergency department. Other strategies for alleviating lingual pain include sucking on cough drops containing benzocaine, phenol, or menthol; cough drops can act like a local anesthetic to numb tongue pain. Once a patient presents to the emergency department, an anesthetic ointment can also assuage thermal injury. As appropriate, prescriptions can be given to patients for 2% lidocaine hydrochloride topical solution to apply to the tongue as needed. Patients should be advised to avoid hot drinks/soup (e.g., hot coffee and hot tea), acidic foods (e.g., tomatoes, vinegar, oranges, pineapples, and other citrus fruits), pepper, chili peppers, and salty items (e.g., potato chips and pretzels), while the tongue is healing.

Chemotherapy and radiation therapy to the head or neck area can also cause burns and sores to the tongue, ranging from slight to severe. An inflammation of the mucous membranes in the mouth (“mucositis”), including inflammation and infections of the tongue’s mucous membranes, may be caused by either radiation therapy or chemotherapy and persist while cancer treatment continues. Care of this condition often includes keeping the mouth clean (i.e., brushing teeth often with a clean, soft-bristle toothbrush and fluoride toothpaste; using a bland antibacterial rinse; removing dentures as much as possible; and, rinsing mouth frequently with sterile water)

## Clinical Feature

and pain management (e.g., topical pain medications, painkillers, and water-soluble lubricating jellies to moisturize the mouth). If a cancer patient presents to the emergency department seeking pain relief related to the tongue, a careful diagnosis of the origin of the pain is important because a cancer patient's pain may come from more than one source (e.g., the cancer itself, the cancer treatment, damage to the nervous system, candidal infection, or medical conditions unrelated to cancer). Non-steroidal anti-inflammatory drugs such as NSAIDs and aspirin-type analgesics should be avoided in patients receiving chemotherapy because these patients have an increased bleeding risk, especially when platelet counts are low.

Patients undergoing cancer treatment who present in emergency departments with tongue injuries may experience delays in healing or difficulty resisting infections because of the indiscriminate damage to healthy cells that results from chemo or radiation therapy. Thankfully, most tongue conditions caused by cancer treatments will resolve within several weeks after treatment stops. To minimize or prevent recurrence of tongue injury during radiation treatment to the head or neck area, radiation specialists and oncologists may supply or approve the use of a mouth guard or dentist-supplied dental tray to block radiation scatter during treatment. According to the American Cancer Society's Cancer Survivors Network, patients who used such devices during

treatment appeared less likely to experience severe burns to their tongues.

Although less common, tongue burns can also be the result of chemical burns caused by acids or bases (also known as "alkalis") that come into contact with tongue tissue, such as lye, bleach, sulfuric acid, sodium hydroxide, potassium hydroxide, and industrial strength cleaning products. The deployment of airbags can also cause alkaline chemical burns when the ash settles on mucous membranes. Clinical symptoms vary widely depending on the type of exposure and offending agent (e.g., hydrofluoric acid exposure may not cause immediate pain). Severity of tissue damage can result in pain and long-term, significant scarring.

Severity of chemical injury to the tongue is generally determined by: (1) the identity of the agent; (2) the agent's pH; (3) the amount of the agent and its concentration; (4) the agent's physical form; (5) duration of contact; (6) existence of other simultaneous or preexisting injury; (7) timing of irrigation; and, (8) extent and thoroughness of irrigation and medical treatment. If the tongue burn is caused by chemical ingestion, clinical priority is to first assess and protect the airway. In the case of children or vulnerable adults, neglect, abuse, or the presence of an illegal activity should be considered when documenting the circumstances surrounding the burn. For example, children may be exposed to caustic agents in methamphetamine ("meth") labs.

*In Warner Bros' classic 1983 movie A Christmas Story, a December "triple dog"-dare results in a boy's tongue being stuck to a flag pole.*



Minnesotans and other “northern climate” patients also are commonly exposed to potential frostbite or freezing-related injuries when their tongue comes into contact with a frozen surface. Such is the case when a child’s tongue sticks to a frozen metal object during winter. Children in cold climates should be taught not to touch their tongue to metal in cold weather. If they touch their tongue to metal and it is 32°F/0°C or less, their tongue will stick. (Basically, the temperature of the metal will freeze the moisture in the tongue to it faster than the body can heat it up.) Once stuck, a person should never forcibly pull their tongue away or a piece of the tongue could be torn off. Instead, have the child breathe in and out slowly to let the warm arm heat the pole enough for the tongue to become unstuck. Hands can be cupped around the area to contain the warm air. If that doesn’t work, try pouring warm water on the tongue and metal and manipulate the tongue with your hands until it becomes unstuck. Most of the time, this situation will require someone else to help free the tongue.

In addition to thermal, chemical, and radiation burns, foods containing capsaicin – an oil found in all chili peppers – can create a sensation of burning that can last for minutes or sometimes hours. Cayenne, jalepeño, and habanero peppers are common forms of chili peppers that can create a burning sensation on the tongue. Whole milk appears to be the most effective method for numbing this sensation because there is a protein in milk (casein) that detaches capsaicin compounds from the nerve receptors on the tongue. If a patient rinses the mouth well with milk and swallows, the tongue, mouth cavity, and throat should feel soothed.

## Multi-Cultural Considerations

As of 2008, about 7% of Minnesota’s population is foreign-born. In contrast, about 13% of the U.S.’s population is foreign-born. About 40% of Minnesota’s foreign-born, immigrant population is Asian according to The Minneapolis Foundation (TMF), with significant representation from Laos, Vietnam, and Korea. Non-Asian immigrants are also making their homes in Minnesota: about 28% are from Latin America, 18% are from Africa; and, 14% are from Europe. A 2010 study by TMF concludes, “Minnesota’s immigrant population is unusually diverse in terms of nationality and immigration status.”

In emergency departments that enjoy culturally diverse patients, health care providers should be sensitive to

the fact that some tongue injuries may be secondary to culturally motivated surgery. For example, well-meaning parents of Asian children living abroad sometimes arrange for a controversial tongue operation (sometimes called a “lingual frenectomy”) to alter or remove a portion of the tongue. For example, it was reported in early 2000 that an increasing number of South Korean parents had arranged for their school-aged children to undergo tongue surgery in the hopes that a “longer and more flexible” tongue would aid English language proficiency. Later, in 2002, BBC News reported, “More and more people in China are seeking tongue operations to improve their English.” Chinese plastic surgeon Dr. Chu Jian disclosed to BBC News that many people in China are seeking tongue operations to help them with their English proficiency; he had recently performed the procedure on a 7 year-old boy hoping for the desired outcome after the Chinese child encountered problems with English pronunciation. By 2004, the South Korean government had become so alarmed by the number of parents having the frenulum (thin tissue under their children’s tongue) snipped to aid English proficiency that it produced and distributed a film emphasizing that “practice” – not surgery – is the answer to language proficiency; linguists pointed out that children of Asian descent raised in English-speaking countries do not have any trouble with English pronunciation. Unfortunately, the surgeries were not eradicated and by 2006 some infants abroad were receiving linguistics-driven tongue surgery.

The idea of altering a tongue for language proficiency is not limited to Asian patients. For example, Rhiannon Brooksbank-Jones received notoriety in 2011 when she underwent surgery on her tongue so she could speak the Korean language without an English accent. Ms. Brooksbank-Jones is Caucasian, English is her native language, and she is from Great Britain. She was 19 years old at the time of her surgery.

## Immigrant Patients

“Death and life are in the power of the tongue.”  
Proverbs 18:21

According to Physicians for Human Rights, every year more than 40,000 people flee torture in their home country and seek safety in the U.S. For example, victims of religious violence in Central Nigeria had their tongues cut out during 2010; during that same year, the president of Darfur threatened to cut off the tongues of international

observers who advocated a delay in Darfur's elections; in 2008, political activists in Zimbabwe had their tongues cut off as part of alleged, state-sponsored violence; during the mid-2000s, amputation of the tongue was approved as a penalty in Iraq for slander or abusive remarks about President Saddam or his family; and, in 1999, the husband of Pakistan's former premier had his tongue cut out while in detention in Karachi.

Minnesota is a designated refugee resettlement area which means that Minnesota has an unusually large refugee population, according to TMF. Almost 45 percent of the immigrants who have been granted legal permanent residency status in Minnesota are refugees or people who sought asylum to avoid persecution in their homeland – or roughly 1 in 5 of Minnesota's new immigrants in recent years. Emergency medical personnel treating patients who have immigrated from regimes marred by violence or persecution should be sensitive to the possibility of past torture or trauma, particularly if the patient has an amputated tongue. Emergency medical personnel should carefully listen to the patient's health concerns, perceptions of need, and medical history without any judgment. Since victims of torture or persecution may feel shame, be distrustful, and find it difficult to ask for help, stress the confidentiality of the medical care they receive. To the extent feasible, emergency medical providers should also educate such patients as to additional health resources available to them.

Finally, the number of undocumented immigrants in Minnesota is unknown. Estimates range from 55,000 to 85,000 according to TMF. This segment of the population may be hesitant to seek necessary emergency medical care for tongue injuries because they fear apprehension by immigration authorities, the denial of services, or because they do not understand English.

## Conclusions

Tongue trauma can be an important clue to other events such as seizures or abuse. The management of lingual lacerations can be challenging, especially in young children who are frightened and unable to cooperate. A physician may repair such wounds in the emergency department with moderate to deep sedation, or may refer to an oral surgeon or ENT specialist for repair in the operating room. Sometimes the best option is to do nothing at all, especially when the wound is no longer bleeding, is small, and does not gape.

## References

- A New Age of Immigrants: Making Immigration Work for Minnesota*, Summary of Key Findings 2010, The Minneapolis Foundation, August 2010, <<http://www.minneapolisfoundation.org/Uploads/CuteEditor/Publications/Community/Immigrationsummary2010.pdf>>, August 23, 2011.
- Bhutto Husband Files Torture Case*, BBC News, February 9, 2005, <[http://news.bbc.co.uk/2/hi/south\\_asia/4251359.stm](http://news.bbc.co.uk/2/hi/south_asia/4251359.stm)>, April 13, 2011.
- Black, Caroline. *Police: Wis. Woman Karen Lueders Bit Off Husband's Tongue, Started Singing Christmas Carols*, CBS News, December 9, 2010, <[http://www.cbsnews.com/8301-504083\\_162-20025063-504083.html](http://www.cbsnews.com/8301-504083_162-20025063-504083.html)>, August 18, 2011.
- Castina. *Tug of War With Pooch Leaves Spencer with Hole in Tongue*. Popcrunch.com, March 4, 2010. <<http://www.popcrunch.com/tug-of-war-with-pooch-leaves-spencer-pratt-with-hole-in-tongue/>>. April 12, 2011.
- Cox, Robert D. *Chemical Burns in Emergency Clinical Presentation*. Medscape Reference. Updated June 28, 2010. <<http://emedicine.medscape.com/article/769336-overview>>, July 12, 2011.
- Demick, Barbara. *A Snip of the Tongue and English is Yours!* Los Angeles Times, April 8, 2002.
- EU Withdraws Darfur Poll Monitors*, BBC News, April 7, 2010, <<http://news.bbc.co.uk/2/hi/africa/8608019.stm>>, April 13, 2011.
- Gambrell, Jon. *Nigeria Violence: 12 Christians Killed, Tongues Cut Out*, Huffpost World, March 17, 2010, <[http://www.huffingtonpost.com/2010/03/17/nigeria-violence-12-chris\\_n\\_502977.html](http://www.huffingtonpost.com/2010/03/17/nigeria-violence-12-chris_n_502977.html)>, April 13, 2011.
- Hawley, Caroline. *Witnesses Describe Zimbabwe Violence*, BBC News, Johannesburg, June 10, 2008, <<http://news.bbc.co.uk/2/hi/africa/7444779.stm>>, April 13, 2011.
- Jin-Kyu Park, 'English Fever' in South Korea: Its History and Symptoms, English Today 97, Vol. 25, No. 1, March 2009, <<http://shawnashapiro.com/EnglishFever.pdf>>, April 13, 2011.
- Jun Sik Kim, Tae Hyun Choi, Nam Gyun Kim, Kyung Suk Lee, Ki Hwan Han, Dae Gu Son, Jun Hyung Kim, Sang-II Lee, and Dawon Kang. *The Replantation of An Amputated*

*Tongue by Supermicrosurgery*, The Journal of Plastic, Reconstructive & Aesthetic Surgery (JPRAS), Volume 60, Issue 10, Pages 1152-1155, October 2007.

Kim, Yahee. *English Fever In Korea: Impacts on the Teaching of English and Social Issues That Arise*, Language, Society and Culture (LSC), Issue 16, 2006, <<http://www.educ.utas.edu.au/users/tle/journal/ARTICLES/2006/16-1.htm>>, April 13, 2011.

Kumar, Neel and Schraga, Erik D. *Complex Laceration, Tongue*. Medscape from WebMD, Medscape Reference, <<http://emedicine.medscape.com/article/83275-overview>>, April 12, 2011.

*Lloyd's Insures Coffee Taster's Tongue for \$13.78 Million*. Insurance Journal, insurancejournal.com, March 9, 2009. <<http://www.insurancejournal.com/news/international/2009/03/09/98524.htm>>, April 12, 2011.

*Woman Bites Tongue Off Alleged Rapist*. NBC LA, June 7, 2009 <<http://www.nbclosangeles.com/news/weird/Woman-Bites-Tongue-Off-Alleged-Rapist---.html>>, April 12, 2011.

Marks, Kathy. *Seoul Tries to Shock Parents Out of Linguistic Surgery*, The Independent, Asia. January 3, 2004. <<http://www.independent.co.uk/news/world/asia/seoul-tries-to-shock-parents-out-of-linguistic-surgery-573153.html>>, April 13, 2011.

Markus, Francis. *Chinese Find Learning English a Snip*, BBC News World Edition. July 31, 2002. <<http://news.bbc.co.uk/2/hi/asia-pacific/2161780.stm>>, April 13, 2011.

*Oral Complications of Chemotherapy and Head/Neck Radiation*, National Cancer Institute at the National Institutes of Health, <<http://www.cancer.gov/cancertopics/pdq/supportivecare/oralcomplications>>, July 12, 2011.

Shubi, Farrid M; Hamza, Omar JM; Kalyanyama, Boniplace M; and, Simon, Elison NM. *Human Bite Injuries in the Oro-Facial Region at the Muhimbili National Hospital*, Tanzania, BMC Oral Health Care 2008, <<http://www.biomedcentral.com/1472-6831/8/12>>, August 19, 2011.

Sorgi, Jay. "Woman Charged with Biting Off Man's Tongue During Kiss." 620 WTMJ NewsRadio, December 7, 2010 <<http://www.620wtmj.com/news/local/111433859.html>>, August 18, 2011.

*Torture*. Physicians for Human Rights, Using Science and Medicine to Stop Human Rights Violations, 2011, <<http://physiciansforhumanrights.org/issues/torture/>>, August 23, 2011.

Zurowski, Cory. *Gerald Landon's Rape Attempt Goes Bad When Victim Bites Off His Tongue*, True Crime Report, June 28, 2011 <[http://www.truecrimereport.com/2011/06/gerard\\_michael\\_landon\\_attempt.php](http://www.truecrimereport.com/2011/06/gerard_michael_landon_attempt.php)>, August 18, 2011.

Benbadis SR et al. Value of Tongue Biting in the Diagnosis of Seizures. *Arch Intern Med*. 155:2346-2349, Nov 27, 1995.

Ulrich J, Maxeiner H. Tongue Bite Injuries—A Diagnostic Criterium for Death in Epileptic Seizure? *Arch Kriminol*. 212:19-29, Jul-Aug, 2003.

## Acknowledgements

The authors would like to thank Ethan Cooper for permission to use his 2011 photograph, "Tasting the Sun," for the cover of *Situation Critical*. Ethan resides in Edina, Minnesota, and attends Eckerd College in St. Petersburg, Florida.

# New Providers in Emergency Medicine

## John W. Lyng, MD, NREMT-P

*Associate Medical Director, North Memorial Ambulance & Air Care  
Staff Physician, Emergency  
Department*

### Education

**Undergraduate:** Mayville State University, Mayville, ND (BS Biology)

### Medical School:

University of North Dakota School of Medicine & Health Sciences

**Residency:** State University of New York (SUNY) Upstate Medical University, Syracuse, NY; Emergency Medicine

**Fellowship:** SUNY Upstate Medical University; EMS & Disaster Medicine

### Professional Experience

Board Certified in Emergency Medicine

Lead Physician – EMS & Pediatric Emergency Medicine – Fairview Ridges Hospital, Burnsville, MN

Attending Physician – University Hospital, SUNY Upstate Medical University, Syracuse, NY

Emergency Physician – Auburn Memorial Hospital, Auburn, NY

### Favorite Part about my Career

I thoroughly enjoy the privilege of being part of the Emergency Department team and caring for the wide variety of patients we see in the ED, from the simple to the complex, young to old, and everything in between. I enjoy both the detective work that must be done to evaluate and appropriately treat complex medical patients, and the hands-on procedural work involved with caring for patients with traumatic injuries. My role as Associate Medical Director for North Memorial Ambulance allows me to feed my interest in medical education and my desire to help improve the care that patients receive before they come to the hospital.

### Interests

Most of my interests involve outdoor activities such as kayaking, running, skiing and fishing. I also enjoy traveling domestically and internationally. I find these activities are all the more memorable when enjoyed with my family and friends.



## Shannon Straszewski, MD

*Staff Physician, Emergency  
Department*

### Education

#### Undergraduate:

University of Wisconsin-Madison

#### Medical School:

University of Wisconsin-Madison

#### Residency:

Beth Israel Deaconess Medical Center/Harvard Affiliated Emergency Medicine Residency



### Favorite Part about my Career

The chance to be a part of a team with the ability to initiate treatment for any patient who presents to the hospital, but at the same time have the opportunity to deliver compassion and support in a chaotic and stressful environment. I like the challenges and diversity in my work and am enthusiastic for the opportunity to learn from my patients and co-workers as I grow in my career.

### Interests

Scuba diving, camping, kayaking, travel, wine and trying new restaurants. Not to forget, as a true Wisconsin girl at heart, I look forward to being in a city where I don't get strange looks when I have seven different types of cheeses in my cart at the grocery store.

# New Providers in Emergency Medicine

## Colleen Kniffin, MD

Staff Physician, Emergency Department

### Education

**Undergraduate:** Wheaton College, Wheaton, Illinois (BA Interdisciplinary Studies: Anthropology, Biology, and Religious Studies)

### Medical School:

University of Minnesota Medical School

### Residency:

Hennepin County Medical Center



### Favorite Part about my Career

The opportunity to walk with patients through some of the most difficult/intense few hours of their lives. In those hours, I hope I can be a good listener, a comfort and a guide for them and their families. I also enjoy the variety of the emergency department. We have the opportunity every day to meet patients who are different from us, work alongside colleagues with various backgrounds and experiences, and see the gamut of diseases. This variety allows me to learn something new every day.

### Interests

Most of my interests revolve around expending my extra energy. I love most activities that involve being active, in nature, and alongside my husband or a good friend. Some of my favorites are camping, whitewater kayaking, road biking, running and snowboarding. I also enjoy experiencing different cultures and exploring the world. I love to travel to other countries!

## Justin Dyer, MD

Staff Physician, Emergency Department

### Education

**Undergraduate:** University of Missouri, Columbia

### Medical School:

University of Missouri, Columbia

### Residency:

Emergency Medicine, Hennepin County Medical Center



### Professional Experience

Emergency Medical Technician for three years in Boone Hospital, Missouri.

### Favorite Part of My Career

I enjoy the personal interaction with my patients.

### Interests

Dogs, canoeing, hiking and golf.

# Partner Profile: The Minnesota State Patrol



In emergency situations, the success of patient outcomes hinges, at least in part, on the medical attention given by first responders. In many cases, the first people to reach accident victims are members of the Minnesota State Patrol.

Since 1977, North Memorial and the Minnesota State Patrol have worked in

partnership to ensure that the members of the force are properly trained to provide the best possible medical attention as first responders to citizens of Minnesota. The State Patrol responds to approximately 8,500 personal injury collisions each year.

“Our philosophy is that the more effective first responders can be, the more effective those in the ambulance can be and the more effective the hospital can be,” says Pat Lilja, MD, medical director of North Memorial Ambulance Services. “Ultimately, it means better care and better outcomes through the entire EMS continuum when first responders are well trained for the emergency situations they encounter.”

North Memorial provides first responder training to new cadets and refresher training to veterans of the force. Last year, EMS training was provided for 41 new cadets and 535 veterans. The standardized training ensures that troopers know what to expect of each other when they arrive at the scene of an emergency.

Training is focused on the types of situations patrolmen are likely to see. Curriculum includes the topic of self care so that officers know what to do in the event they or their partners are shot or stabbed until help arrives. Another example is educating officers on the difference between emergencies created by a driver who has consumed alcohol versus a driver who is having a diabetic emergency.

“The partnership with North Memorial has allowed us to work together in training environments and in the field to enhance emergency medical services delivered to the public,” says Captain Craig Hendrickson of the Minnesota State Patrol. “This includes leveraging resources, scene management, sharing information and improving coordinated emergency responses.”

In recent years, the State Patrol and North Memorial’s EMS Education have worked collaboratively to share resources for training driving instructors. The State Patrol has made their driving simulators available to North Memorial ambulance driving instructors, who have gone on to train drivers in various regions throughout the state. “This is just one example of how our partnership continues to grow to make our members and Minnesota a safer state,” says Captain Hendrickson.

Each year, approximately twenty state troopers are recognized for saving a life, a tangible reminder of the importance of the training provided by North Memorial. Captain Hendrickson estimates that hundreds of lives have been saved by the efforts of troopers trained by North Memorial’s emergency medical services instructors.

“This has been a very productive partnership,” says Dr. Lilja. “Over the years, we’ve seen on a regular basis how the training we’ve provided has helped to truly save lives.”





# North Memorial

**Emergency and Trauma Services**

3300 Oakdale Ave. N.  
Robbinsdale, MN 55422

**Please share this with your staff.**

Non-Profit Org.  
U.S. Postage  
PAID  
Minneapolis, MN  
Permit No. 3784